

Take this wound
to the grave
my dear,
AGAIN !!

Case study

- Holistic care of a community patient with a stage 4 pressure ulcer.
- Multiple co-morbidities and complex needs.
- 5 months hospitalisation for surgical debridement of her wound.

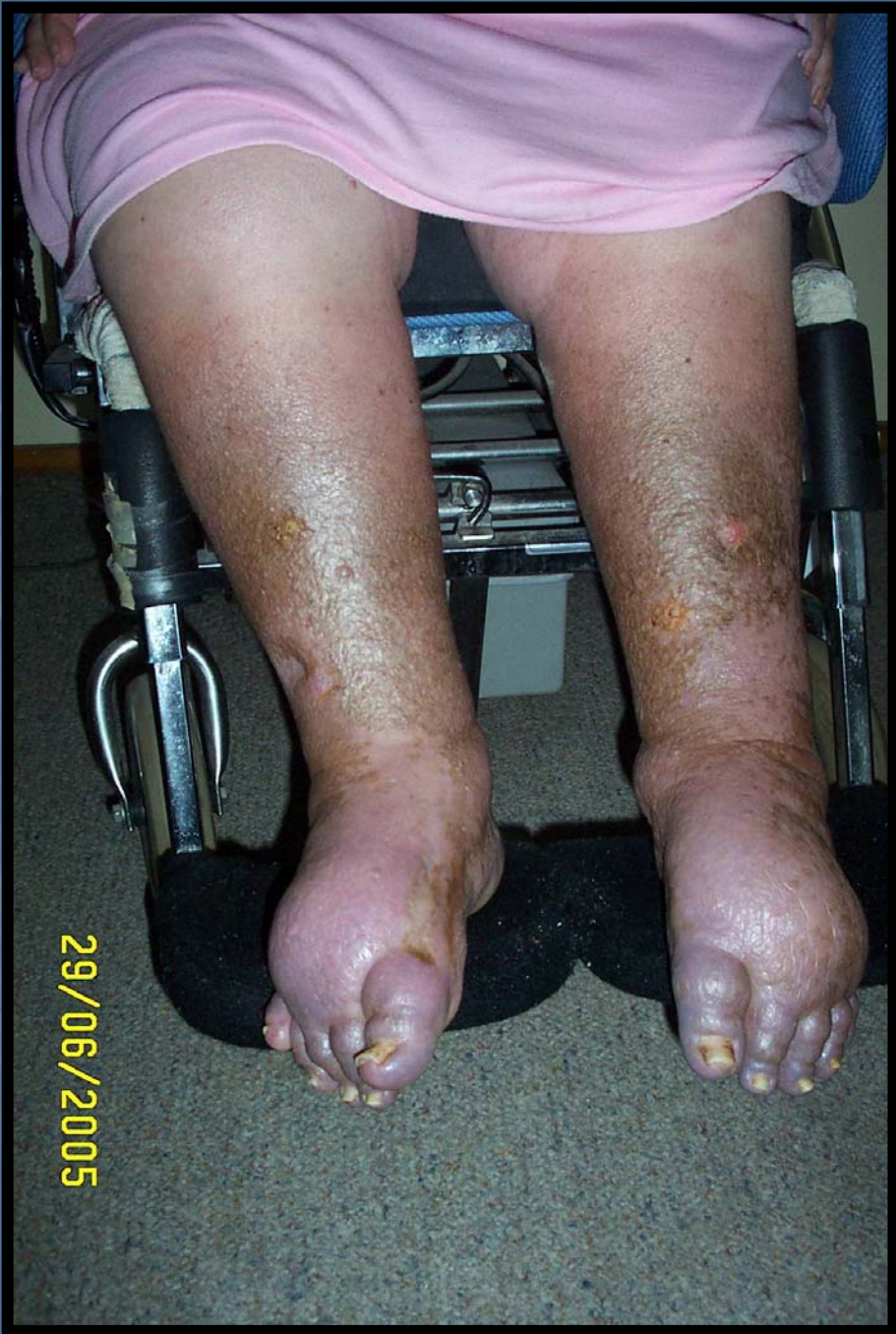- Lung condition worsened
- Told wound would be unlikely to heal
- Sent home to the care of her family to be happy while she died

HISTORY (brief version)

- Rheumatoid arthritis
- Asthma
- Pulmonary oedema
- Bronchiectasis
- Chronic venous insufficiency
- Morbid obesity
- Hypertension
- Atrial fibrillation

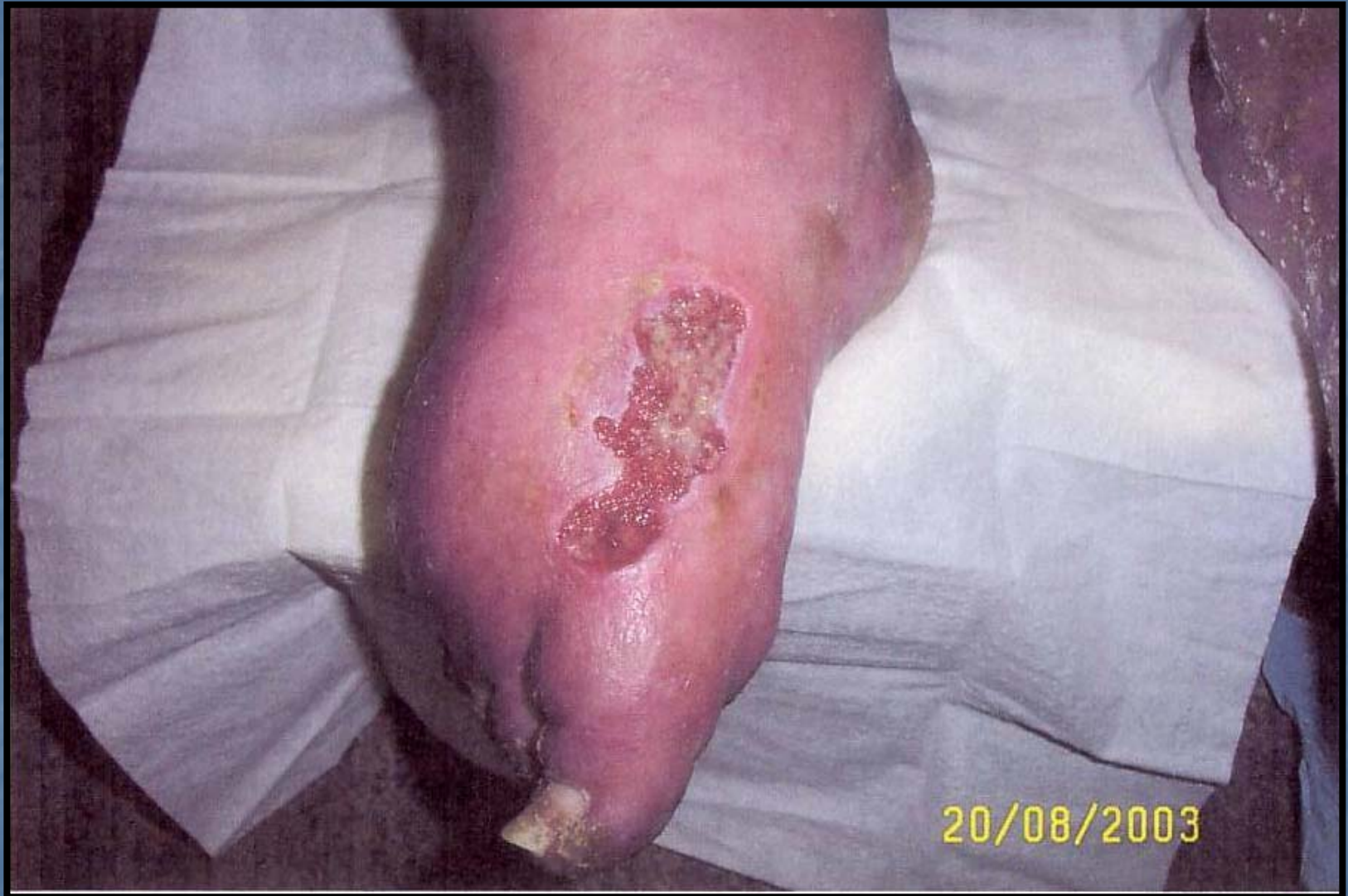CHALLENGES

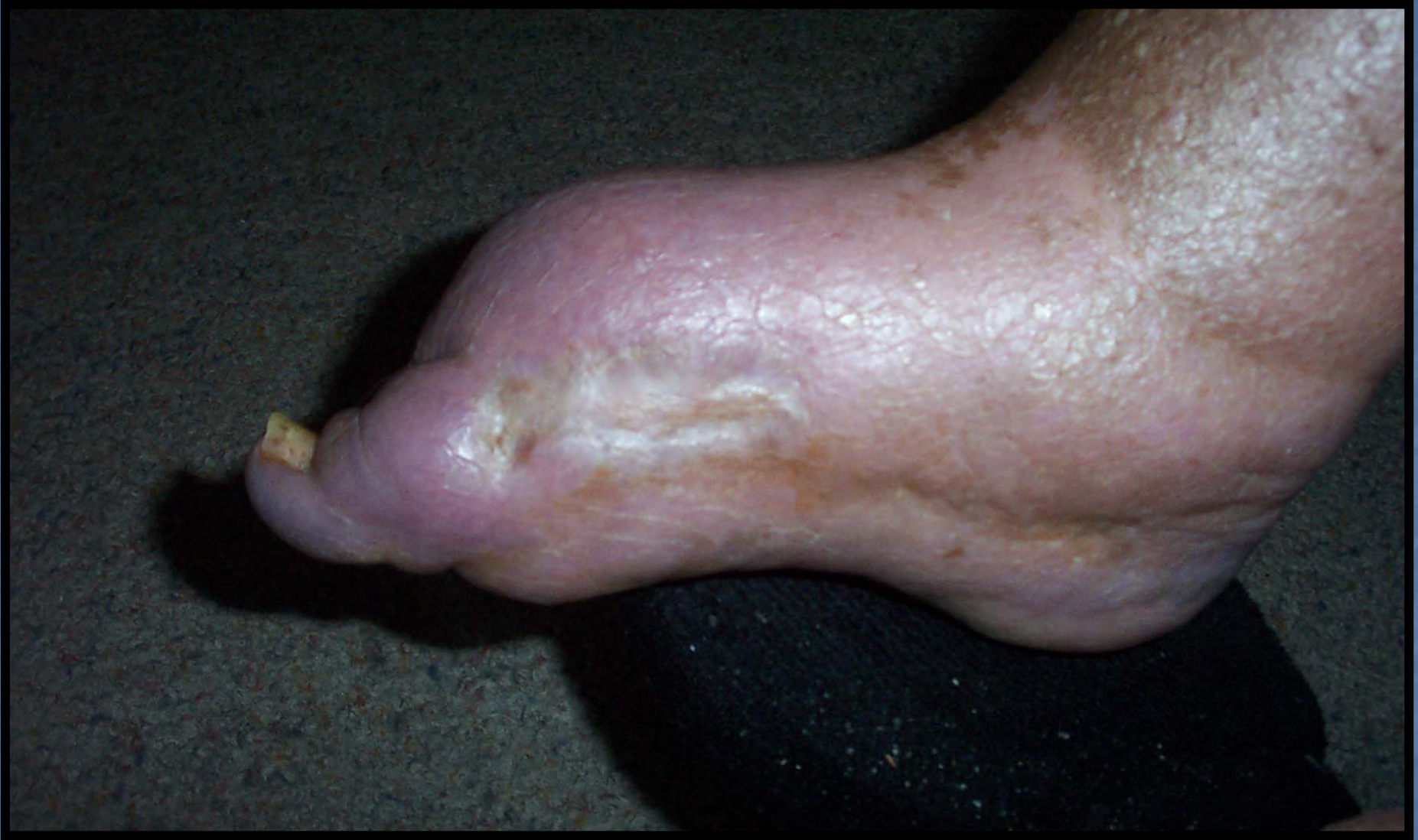- Wheelchair bound
 - Hoist transfers
 - Fragile skin
 - Lung diseases



PREVIOUS WOUND

- Minor trauma to foot – became a deep wound
- “IT WILL NEVER HEAL”
- Teamwork & discussion
- Two primary care nurses
- Supportive GP






PARTY TIME

wait

there's more

ok

we can handle this



HOSPITAL

- Buttock, tracking sinus-stage 4
- Surgical debridement & vacuum
- Heart failure/ Renal Failure
- Pulmonary oedema
- Bronchiectasis - infection
- Dietician, physiotherapist
- Indwelling catheter

AIMS

- Home
- Daily dressing
- Protect skin
- Continent
- Family support

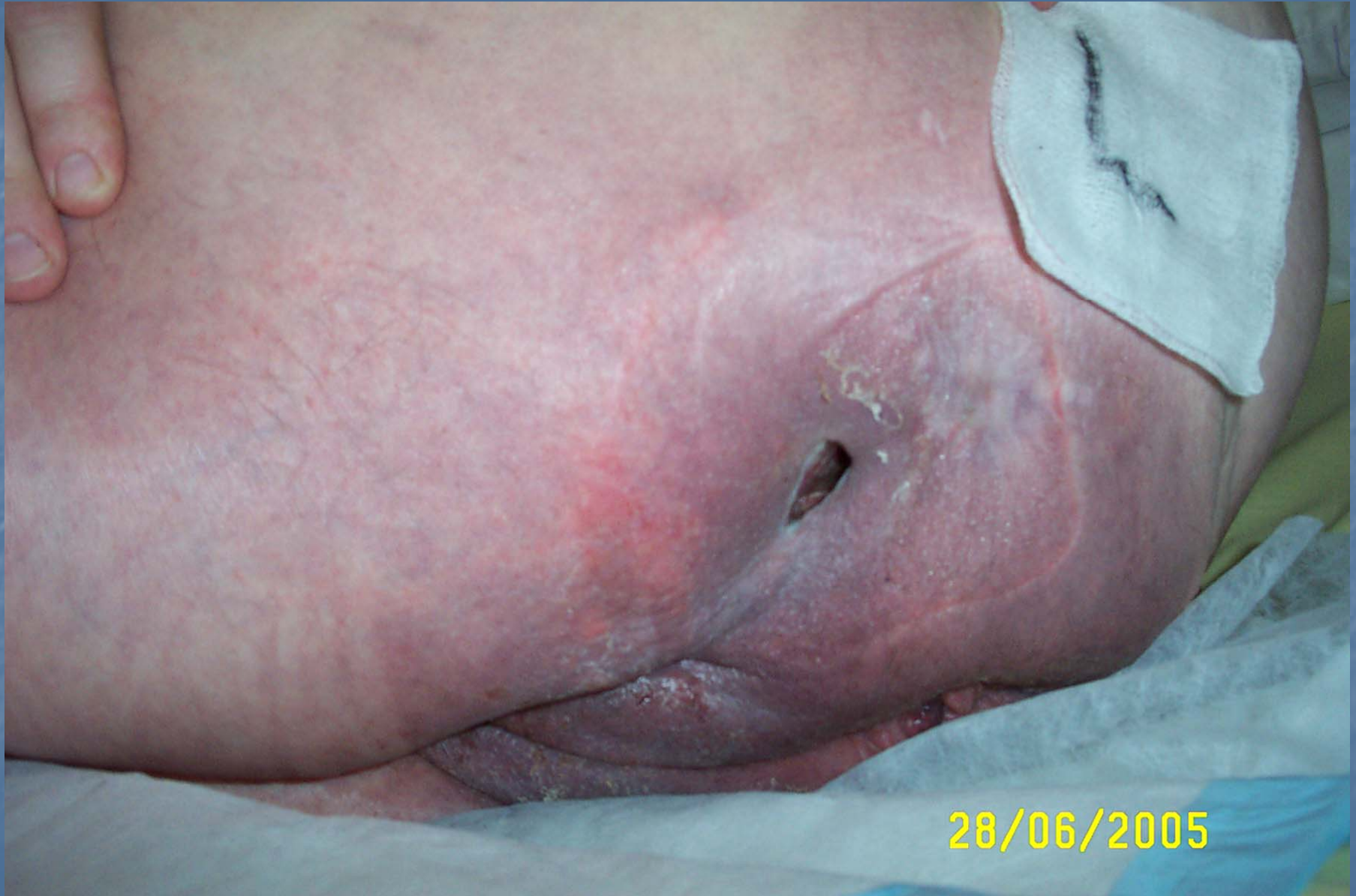Home as palliative client

Positives

- Teamwork
 - .CNC wounds RHH
 - .Community nurses
 - .Daughter
 - .G P
- Familiarity
- Trust
- Belief in ourselves
- Patients resilience
- Home Oxygen

Negatives

- Medical conditions
- Seated position
- Cost of dressings
- Fragile skin
- Staff illness
- Two people



HELP!



THERE'S ANOTHER ONE

POSTPONE THE PARTY

BEG, STEAL or BORROW

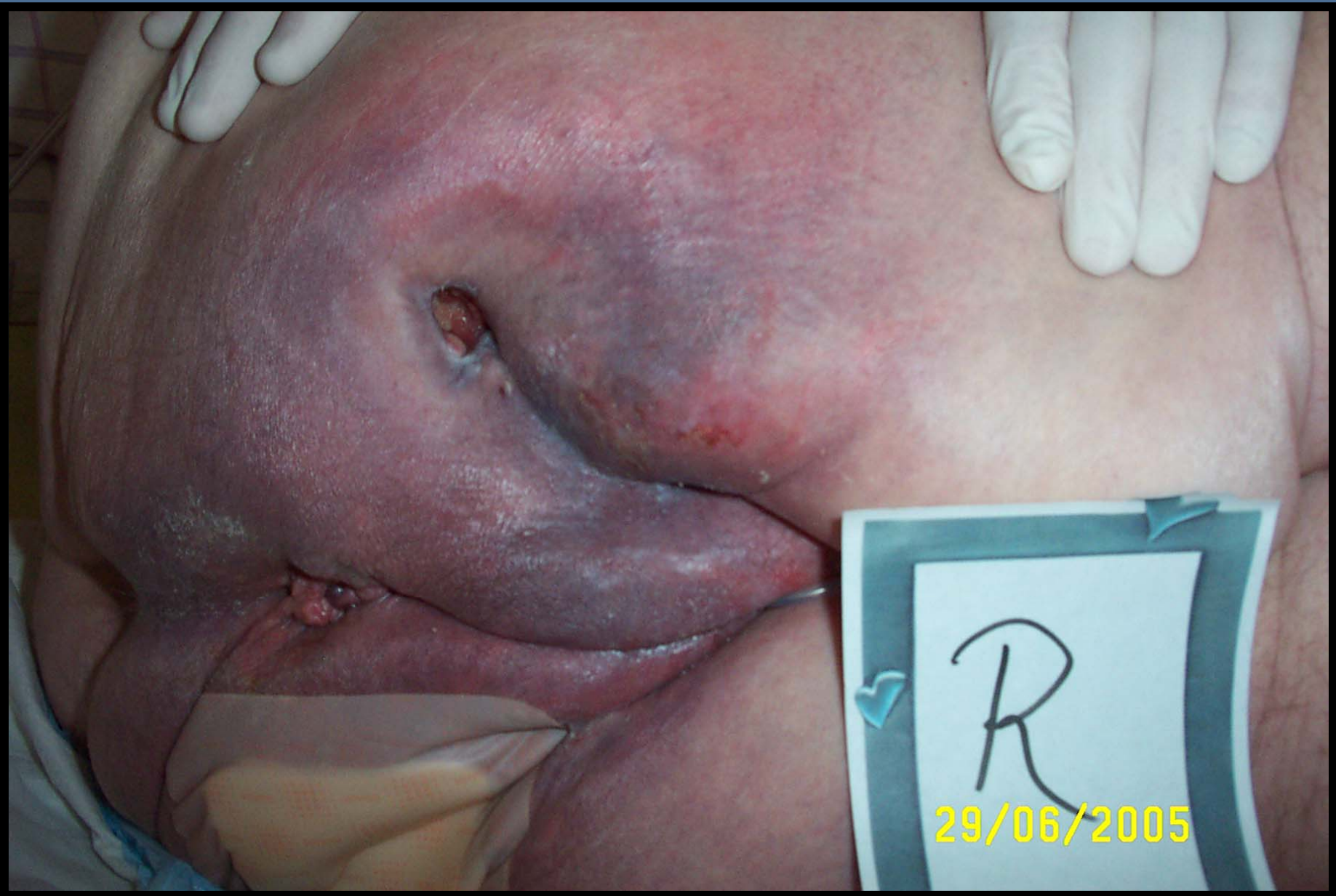Same area, opposite side

Same problems

Cost

Skin care





PROGRESS REPORT

- Wound 1
- Wound 2
- General health
- General wellbeing

Indulge

(Involve)

Rejuvenate

MOTHER
&
DAUGHTER

BOTH
DOING
WELL

